

Role of *HER-2/neu* in Premalignant and Malignant Lesions of Uterine Cervix

SWASTI BAJPAI¹, SEEMA AWASTHI², SHYAMOLI DUTTA³, ANKITA MITTAL⁴, ASHUTOSH KUMAR⁵, FAIYAZ AHMAD⁶

ABSTRACT

Introduction: In light of literature and controversy that exists in various cervical lesions, this prospective study was designed to explore the expression of Human Epidermal Growth Factor Receptor-2 (*HER-2/neu*) in the cervical lesions and its correlation with the histopathological grade and type of tumour. Immunohistochemistry (IHC) was performed to evaluate *HER-2/neu* expression as it is the most reliable method of detecting overexpression of *HER-2/neu*.

Aim: To assess the role of *HER-2/neu* expression in premalignant and malignant lesions of uterine cervix.

Materials and Methods: Seventy cases of premalignant and malignant cervical lesions received in our department from January 2015 to December 2016, were included in study and Polyclonal Rabbit Anti-Human c-erbB-2 oncoprotein from DAKO was used. Standard streptavidin-biotin peroxidase method of IHC was followed. A golden brown membrane and cytoplasmic staining was taken as a positive reaction and intensity of expression was graded according to the 2014 ASCO/CAP guidelines for *HER-2/neu* reporting.

Results: Out of total 70 cases, *HER-2/neu* expression scores were 0 in 64.3% {23 cases of Cervical Intraepithelial Neoplasia (CIN) and 22 of Squamous Cell Carcinoma (SCC)}, +1 in 22.9%, (04 cases of CIN and 12 of SCC) +2 in 10% (06 cases of SCC and 01 of adenosquamous carcinoma) and +3 in 2.9% (02 cases of adenocarcinoma) cases. *HER-2/neu* overexpression rate was significantly higher in malignant (48.8%) as compared to pre malignant (14.8%) cases ($p=0.004$) and expression scores were higher (+2 and +3) in 20.9% of malignant cases as compared to none of pre malignant cases ($p=0.020$). Significant higher *HER-2/neu* scores are seen (+2 and +3) in all the adenocarcinoma cases as compared to 15% cases of SCC ($p<0.001$). Among malignant cases, *HER-2/neu* expression was statistically significantly higher in {Moderately Differentiated (MD) + Poorly Differentiated (PD)} 59.09% as compared to {Well Differentiated (WD)} 38.09% cases ($p=0.090$).

Conclusion: Study shows that expression of *HER-2/neu* is relatively lower in cervical lesions. However, the results of our study show that with shift from well to poorly differentiated lesions; the *HER-2/neu* expression rate shows an incremental trend.

Keywords: Cervical carcinoma, Immunohistochemistry, Oncoprotein, Overexpression

INTRODUCTION

Cervical and ovarian cancers are the most common gynecological cancers affecting women worldwide and in India. Cervical cancer is on a declining trend, but remains the second most common cancer in women after breast cancer. Every year in India, 122,844 women are diagnosed with cervical cancer and 67,477 die from this disease [1]. The high burden of cervical cancer in developing nations like India is attributed primarily to lack of awareness programs, no formal screening programs and thus most women present in the late stages of cervical cancer.

The exploration of new markers with prognostic or predictive value is of vital significance in the development of effectual anti-cancer therapies. The HER family is one of the most widely studied growth receptor families [2]. *HER-2/neu* is a membrane-bound receptor with tyrosine-kinase activity [3,4] and plays a crucial part in malignant transformation and carcinogenesis by interacting with the other members of the HER family to potentiate intracellular signaling [5,6].

Other than its role in progression of many malignancies, it has also been deeply assessed as a therapeutic target. Role of *HER-2/neu* expression in gynaecological malignancies is still being researched [7-9] to evolve a consensus.

Our study was designed to explore the utility of IHC for the assessment of *HER-2/neu* oncoprotein in the premalignant and malignant lesions of uterine cervix and the correlation of these receptors with the tumour type and grade of the tumour at the time of diagnosis.

MATERIALS AND METHODS

This prospective study was carried out from January 2015 to December 2016 at Teerthanker Mahaveer Medical College and Research Center, Moradabad, Uttar Pradesh, India, after getting ethical clearance from the Institutional Ethical Committee.

A total of 70 diagnosed cases of premalignant and malignant lesions of uterine cervix were enrolled in the study. Cases of inflammatory lesions and metaplasia of uterine cervix were excluded. Among these 27 were premalignant (10 CIN-I, 9 CIN-II and 8 CIN-III) and 43 were malignant (one adenosquamous carcinoma, two adenocarcinoma and 40 squamous cell carcinoma).

All the patients included in this study were subjected to standard diagnostic criteria including detailed history, physical examination and subsequently histological diagnosis. Paraffin blocks of the above selected cases were taken for Haematoxylin and Eosin staining and reviewed.

After confirming and noting the diagnosis and microscopy details, sections were taken for immunohistochemical *HER-2/neu* and golden brown colour membrane and cytoplasmic staining was taken as a positive reaction. Intensity of *HER-2/neu* expression was graded according to 2014 ASCO/CAP guidelines for *HER-2/neu* reporting [Table/Fig-1] [10].

STATISTICAL ANALYSIS

Data was analysed using SPSS version 20.0. Chi-square test was used for comparison of data. A p -value < 0.05 was considered statistically significant.

RESULTS

Among 35.7% of *HER-2/neu* positive cases, *HER-2/neu* expression scores were 0 in 64.3% (23 cases of CIN and 22 cases of SCC), +1 in 22.9%, (four cases of CIN and 12 cases of SCC) +2 in 10% (six cases of SCC and one case of adenocarcinoma) and +3 in 2.9% (two cases of adenocarcinoma) patients [Table/Fig-2].

HER-2/neu overexpression rate was significantly higher in malignant (48.8%) as compared to premalignant (14.8%) cases ($p=0.004$) and *HER-2/neu* expression scores were higher (+2 and +3) in 20.9% of malignant cases as compared to none of premalignant cases, thus showing a significant difference ($p=0.020$).

HER-2/neu positivity in CIN was 14.8% and it was only of +1 type, 45.0% in SCC which varied from +1 (12 cases) to +2 (six cases) [Table/Fig-3] and 100% positivity in adenocarcinoma and its variants which varied from +2 (one case) to +3 (two cases) [Table/Fig-4] but this difference was not significant statistically.

Higher *HER-2/neu* scores (+2 and +3) were seen in all the adenocarcinoma cases (100%) as compared to only 15% cases of SCC and this difference was significant statistically too ($p<0.001$) [Table/Fig-2].

Intensity of HER-2 expression	Characteristic features
0	No staining is observed or shows membrane staining that is incomplete and is faint/barely perceptible and within <10% of tumour cells.
1+	Membrane staining that is incomplete and is faint/barely perceptible and within >10% of tumour cells.
2+	Circumferential staining that is incomplete and/or weak/moderate within > 10% of tumour cells or complete intense circumferential membrane staining within < 10% of tumour cells.
3+	Complete intense circumferential membrane staining within > 10% of tumour cells.

[Table/Fig-1]: The 2014 ASCO/CAP HER-2 reporting guideline.

Among premalignant cases, *HER-2/neu* expression scores did not show a significant association with CIN grades while among malignant cases, *HER-2/neu* expression was appreciably higher in (MD and PD) 59.09% as compared to (WD) 38.09% cases but association was not significant statistically ($p=0.090$) [Table/Fig-2].

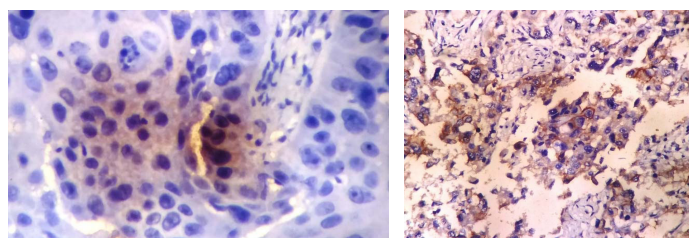
DISCUSSION

In the light of the literature and controversy that exists regarding the expression of *HER-2/neu* in various disorders of the cervix, this prospective study was designed to explore the expression of *HER-2/neu* oncoprotein in the cervical lesions and the correlation of these receptors with the histopathological grade and type of the tumour at the time of diagnosis. In the present study, we included only 23 premalignant and 47 malignant lesions and ruled out chronic cervicitis and metaplasia. In our study SCC cases (57.1%) outnumbered the adenocarcinoma cases (4.28%) which was in concordance to World Health Organization (WHO) too which states that squamous cell carcinomas account for ~70%–80% of cervical cancers while adenocarcinomas for 10%–15% [11].

Overall expression of *HER-2/neu*: In present study, *HER-2/neu* expression was seen in 35.7% and rest 64.3% did not show any positivity for *HER-2/neu*. A substantial difference in *HER-2/neu* overexpression in uterine cervical lesions has been shown in different contemporary studies. The positivity rate in present study is close to that reported by Sharma N et al., and Sarvade P et al., who reported positivity rate of 36.6% and 44% respectively [12,13]. The low positivity rate (0.006%) in the study of Conesa-Zamora P et al., could be attributed to strict criteria used by them wherein only a score of 3+ was considered as positive [14].

S No.	Variable	Total	HER-2/neu Expression Scores				p-value
			0	+1	+2	+3	
1.	Overall	70	45 (64.3%)	16 (22.9%)	7 (10.0%)	2 (2.9%)	--
2.	Status						
	Premalignant	27	23 (85.2%)	4 (14.8%)	0	0	0.020
	Malignant	43	22 (51.2%)	12 (27.9%)	7 (16.3%)	2 (4.7%)	
3.	Premalignant						
	CIN I	10	0	0	0	0	0.248
	CIN II	9	0	2 (22.2%)	0	0	
	CIN III	8	0	2 (25.0%)	0	0	
4.	Malignant						
	Adenocarcinoma/ Adenosquamous carcinoma	3	0	0	1 (33.3%)	2 (66.7%)	<0.001
	Squamous cell carcinoma	40	22 (55.0%)	12 (30.0%)	6 (15.0%)	0	
5.	Histopathological Grade (n=43)						
	Well differentiated	21	13 (61.9%)	5 (23.8%)	3 (14.3%)	0	0.014
	Moderately differentiated	15	8 (53.3%)	5 (33.3%)	0	2 (13.3%)	
	Poorly differentiated	7	1 (14.3%)	2 (28.6%)	4 (57.1%)	0	

[Table/Fig-2]: Correlation of *HER-2/neu* overexpression with characteristics of premalignant and malignant lesions.



[Table/Fig-3]: Showing +2 *HER-2/neu* expression score in a case of cervical squamous cell carcinoma (IHC; 400X magnification). [Table/Fig-4]: Showing +3 *HER-2/neu* expression score in a case of cervical adenocarcinoma (IHC; 400X magnification). (Images from left to right)

In present study, overexpression rate was significantly higher ($p=0.020$) in malignant cases (48.8%) as compared to premalignant cases (14.8%).

***HER-2/neu* expression and IHC scores:** With respect to expression of scores, the number of cases with scores 2 and 3 were significantly higher in malignant lesions (21%) as compared to nil (0%) in premalignant lesions ($p=0.020$) [Table/Fig-2]. All the premalignant cases showed *HER-2/neu* overexpression score upto +1 only. Compared to findings of present study, in their study Joseph T and Raghuveer VC noted *HER-2/neu* overexpression in 70% of premalignant and 100% of malignant cases [15]. In their study, out of seven positive cases of CIN, four had score 1+ and remaining three had score 2+ whereas in 24 positive malignant cases, 22 (91.7%) had score 2+ and 3+, thus showing that higher scores are indicative of more severe form of cervical cancer. However, according to Sarvade P et al., no *HER-2/neu* overexpression was observed for any of the CIN cases (0%) whereas for malignant cases, the overexpression rate was 56.1% [13]. Thus, showing overexpression rate in

malignant lesions to be closer to that observed in the present study (48.8%).

Premalignant and malignant lesions: Higher expression of *HER-2/neu* among malignant as compared to premalignant lesions in our study is in agreement with the findings of Sarvade P et al. and Carreras R et al., [13,16] and indicated the possibility of gradual progression in *HER-2/neu* expression from premalignant to malignant cases although several previous studies [17] do not endorse the same in terms of positivity alone. In his study, Gupta et al., also expressed similar concerns regarding the usefulness of *HER-2/neu* overexpression [18].

All the adenocarcinoma (100%) cases had IHC score 2 or 3 as compared to only 15% cases of squamous cell carcinoma had the same score, thus showing a significant difference [Table/Fig-2]. In contrast, Joseph T and Raghuvver VC who in their study reported 100% positivity rate for both adenocarcinoma as well as squamous cell carcinoma cases [15]. However, similar to our study, the lesser IHC score of 1+ was reported only in 10% SCC cases, thus indicating no differentiation capability of either IHC overexpression as well as the score in their study sample. Contrary to findings of both present study and that of Sharma N et al., and Joseph T and Raghuvver VC, in their study found none of the adenocarcinoma cases to be IHC positive [12,15] whereas for SCC cases, this rate was 61.1% and for adenosquamous carcinoma this rate was 50%. In another study, by Sarvade P et al., the positivity rate for adenocarcinoma, adenosquamous cell carcinoma and SCC was 60%, 0% and 56.7% respectively [13].

The findings of present study, thus do not show harmony with any of the previous studies except some resemblance with the study of Gupta N et al., who reported a positivity rate of 84.62% for adenocarcinoma as compared to only 54.17% for squamous cell carcinoma and a higher proportion of IHC scores 2+ and 3+ for adenocarcinoma (61.54%) as compared to SCC (43.8%) [18]. In fact, all the studies show different trends, thus indicating that these trends need to be followed further using larger sample sizes. Many studies on cervical lesions are of the opinion that *HER-2/neu* overexpression is directly linked to advanced grades and poorly differentiated tumour and having bad outcomes [19,20].

***HER-2/neu* expression and grade of tumour:** In present study, *HER-2/neu* positivity rate showed an incremental trend from well differentiated (28.1%) to poorly differentiated (85.7%) malignant lesions. However, the association was not considerable statistically. However, with respect to higher scores 2 and 3, the proportion of cases with higher scores (2 and 3) was significantly higher in poorly differentiated grade (57.1%) as compared to well differentiated (14.3%) and moderately differentiated (13.3%) cases [Table/Fig-2].

Contrary to these findings, Joseph T and Raghuvver VC in their study reported 100% positivity rate for all the histopathological grades [15], however, with respect to IHC scores, they also reported an increasing trend of higher scores (3+) increasing from 0% (well differentiated) and 27.3% (moderately differentiated) to 72.7% (poorly differentiated) histopathological grades respectively. Gupta N et al., like our study also correlated *HER-2/neu* expression in various grades of 48 cases of SCC uterine cervix [18]. Expression was found to be 0% in well differentiated, 55% in moderately differentiated and 80% in poorly differentiated type of SCC. Sharma N et al., and Sarvade P et al., also reported similar trend of *HER-2/neu* expression [12,13]. Thus, the findings of present study are in agreement with the literature and show that with increasing loss of differentiation, the *HER-2/neu* IHC expression rate shows an incremental trend.

LIMITATION

One of the limitations of present study is a small sample size. In view of this small sample size, especially of premalignant lesions, most of the evidence are restricted to study of trends only and has not been established statistically. Even for meta-analysis and pooled analysis, the data on the issue is insufficient, hence further studies on larger sample size are recommended.

Considerable heterogeneity in the distribution of immunoreactive tumour cells could also be accountable for such conflicting reports on *HER-2/neu* expression in uterine lesions.

CONCLUSION

In conclusion, our study indicates that expression of *HER-2/neu* is relatively lower in cervical lesions. With shift from well to poorly differentiated lesions, the *HER-2/neu* expression rate shows an incremental trend. Immunohistochemical verdict of *HER-2/neu* expression do not distinguish subgroups of patients at higher risk of recurrence of disease. Additionally, this oncogene may not represent a future target for monoclonal antibody directed therapy for cervical cancer but still further studies on the issue are required before making a consensus.

ACKNOWLEDGEMENTS

The authors thank the Department of Pathology, Teerthanker Mahaveer Medical College and Research Center, Moradabad, for their kind and generous support for this research work.

REFERENCES

- [1] ICO Information Centre on HPV and Cancer (Summary Report 2014-08-22). Human Papillomavirus and Related Diseases in India; 2014.
- [2] Aaronson SA. Growth factors and cancer. *Science*. 1991;254:1146-53.
- [3] Coussens L, Yang-Feng TL, Liao YC, Chen E, Gray A, McGrath J, et al. Tyrosine kinase receptor with extensive homology to EGF receptor shares chromosomal location with neu oncogene. *Science*. 1985;230:1132-39.
- [4] Akiyama T, Sudo C, Ogawara H, Toyoshima K, Yamamoto T. The product of the c-erbB-2 gene: A 185-kilodalton glycoprotein with tyrosine kinase activity. *Science*. 1986;232:1644-46.
- [5] Bargmann CI, Hung MC, Weinberg RA. The neu oncogene encodes an epidermal growth factor receptor-related protein. *Nature*. 1986;319:226-30.
- [6] Graus-Porta D, Beerli RR, Daly JM, Hynes NE. ErbB-2, the preferred heterodimerization partner of all ErbB receptors, is a mediator of lateral signaling. *EMBOJ*. 1997;16:1647-55.
- [7] Yazici H, Dolapcioglu K, Buyru F, Dalay N. Utility of c-erbB-2 expression in tissue and sera of ovarian cancer patients. *Cancer Invest*. 2000;18(2):110-14.
- [8] Tuefferd M, Couturier J, Penault-Llorca F, Vincent-Salomon A, Broët P, Guastalla JP. HER2 status in ovarian carcinomas: A multicenter GINECO study of 320 patients. *PLoS One*. 2007;2(11):e1138.
- [9] Cirisano FD, Karlan BY. The role of the *HER-2/neu* oncogene in gynecologic cancers. *J Soc Gynecol Investig*. 1996;3(3):99-105.
- [10] Wolff AC, Hammond MEH, Hicks DG, Dowsett M, McShane LM, Allison KH, et al. Recommendations for human epidermal growth factor receptor 2 testing in breast cancer. american society of clinical oncology/college of American pathologists clinical practice guideline update. *Arch Pathol Lab Med*. 2014;138:241-56.
- [11] Colombo N, Carinelli S, Colombo A, Marini C, Rollo D, Sessa C. Cervical cancer: ESMO Clinical Practice Guidelines for diagnosis, treatment and follow-up. *Ann Oncol*. 2012;23(7):vii27-vii32.
- [12] Sharma N, Kaushik A, Sumanashree, Sharma U. Evaluation of HER-2 neu Over Expression in Morphological Variants of Cervical Carcinoma: A Study of 25 Cases. *AABS*. 2016;3(2):A207-A213.
- [13] Sarvade P, Patil S, Bindu R. Immunohistochemistry study for *HER-2/neu* expression in lesions of uterine cervix. *IJCRR*. 2016;8(13):50-57.
- [14] Conesa-Zamora P, Torres-Moreno D, Isaac MA, Perez-Guillermo M. Gene amplification & immunohistochemical expression of ERBB2 and EGFR in cervical carcinogenesis. Correlation with cell-cycle markers and HPV presence. *Exp Mol Pathol*. 2013;95(2):151-55.
- [15] Joseph T, Raghuvver VC. HER2/neu expression in cervical intraepithelial neoplasia and cervical carcinoma. *Int J Biomed Adv Res*. 2015;6(1):47-52.
- [16] Carreras R, Alameda F, Mancebo G, Garcia- Moreno P, Mariñoso MLM, Costa C, et al. A study of Ki-67, c-erbB2 and cyclin D-1 expression in CIN-I, CIN-III and squamous cell carcinoma of the cervix. *Histopathol*. 2007;22:587-92.
- [17] Califano D, Losito S, Pisano C, Santelli G, Gregg S, Iodice F, et al. Significance of erbB-2 immunoreactivity in cervical cancer. *Front Biosci*. 2006;1:2071-76.

- [18] Gupta N, Singh S, Marwah N, Kumar S, Chabra S, Sen R. *HER-2/neu* expression in lesions of uterine cervix: is it reliable and consistent? Indian J Pathol Microbiol. 2009;52(4):482-85.
- [19] Nevin J, Laing D, Kaye P, McCulloch T, Barnard R, Silcocks P, et al. The significance of Erb-b2 immunostaining in cervical cancer. Gynecol Oncol. 1999;73:354-58.
- [20] Niibe Y, Nakano T, Ohno T, Suzuki Y, Oka K, Tsujii H. Prognostic significance of C-erb B-2/HER2 expression in advanced uterine cervical carcinoma with para-aortic lymph node metastasis treated with radiation therapy. Int J Gynecol Cancer. 2003;13:849-55.

PARTICULARS OF CONTRIBUTORS:

1. Postgraduate Student, Department of Pathology, Teerthanker Mahaveer Medical College and Research Center, Moradabad, Uttar Pradesh, India.
2. Professor, Department of Pathology, Teerthanker Mahaveer Medical College and Research Center, Moradabad, Uttar Pradesh, India.
3. Professor and Head, Department of Pathology, Teerthanker Mahaveer Medical College and Research Center, Moradabad, Uttar Pradesh, India.
4. Assistant Professor, Department of Pathology, Teerthanker Mahaveer Medical College and Research Center, Moradabad, Uttar Pradesh, India.
5. Assistant Professor, Department of Pathology, Teerthanker Mahaveer Medical College and Research Center, Moradabad, Uttar Pradesh, India.
6. Assistant Professor, Department of Pathology, Teerthanker Mahaveer Medical College and Research Center, Moradabad, Uttar Pradesh, India.

NAME, ADDRESS, E-MAIL ID OF THE CORRESPONDING AUTHOR:

Dr. Seema Awasthi,
Professor, Faculty Block-B, 201, Teerthanker Mahaveer University Campus, Moradabad-244001, Uttar Pradesh, India.
E-mail: dr.seemaabhishek@yahoo.com

Date of Submission: **Jan 05, 2017**Date of Peer Review: **Feb 13, 2017**Date of Acceptance: **May 31, 2017**Date of Publishing: **Sep 01, 2017****FINANCIAL OR OTHER COMPETING INTERESTS:** None.